

Potency of Fetal Bovine Serum on Modified Jones Culture Medium in The Diagnosis of Blastocystis Hominis: A Study on Morphological Features and Ph Test

Kadek Intan Arta Sarita¹, Putu Sathiya Adi Janendra², Kadek Indira Maheswari³, Kadek Edy Sukarma⁴, Made Bayu Permasutha^{5*}, Made Kurnia Widiastuti Giri⁶ 

^{1,2,3,4} Study Program of Medicine, Universitas Pendidikan Ganesha, Buleleng, Bali, Indonesia

⁵ Parasitology Division, Department of Biomedical Sciences, Faculty of Medicine, Universitas Pendidikan Ganesha, Indonesia

⁶ Department of Public Health, Faculty of Medicine, Universitas Pendidikan Ganesha, Indonesia

ARTICLE INFO

Article history:

Received January 18, 2024

Accepted April 13, 2024

Available online April 25, 2024

Kata Kunci:

Blastocystis Hominis, Fetal Bovine Serum, Medium Kultur Jones

Keywords:

Blastocystis Hominis, Fetal Bovine Serum, Medium Kultur Jones



This is an open access article under the [CC BY-SA](https://creativecommons.org/licenses/by-sa/4.0/) license.

Copyright © 2024 by Author. Published by Universitas Pendidikan Ganesha.

ABSTRAK

Diare merupakan penyebab kematian ketiga di dunia pada anak di bawah 5 tahun. Diare disebabkan oleh infeksi bakteri, virus, hingga parasit yang mengganggu sistem pencernaan. Diare akibat parasit terbanyak disebabkan oleh Blastocystis hominis. Sehingga perlu dilakukan penelitian terkait morfologi Blastocystis hominis untuk membantu menegakan diagnosis penyebab diare. Penelitian ini merupakan penelitian eksperimental yang dilakukan pada medium kultur Jones yang telah dimodifikasi dengan fetal bovine serum dalam lima kelompok uji dengan konsentrasi P1 (0.1 mL), P2 (0.5 mL), P3 (1.0 mL), P4 (1.5 mL), dan P5 (2.0 mL). Temuan morfologi Blastocystis hominis pada masing-masing kelompok uji dengan rerata pH c menunjukkan hasil yang optimal pada pemeriksaan mikroskopis dengan nilai $P > 0.05$ pada uji t dua sampel berpasangan. Sedangkan, kelompok uji P5 (6.15) menunjukkan perbedaan bermakna dengan nilai $P < 0.001$ dengan baku emas. fetal bovine serum dapat digunakan pada konsentrasi 0.1 mL dengan pH 7.29 untuk kebutuhan klinis karena sudah mampu menunjukkan temuan morfologi.

ABSTRACT

Diarrhea is the third leading cause of death among children under the age of five worldwide. Diarrhea can result from bacterial infections, viral infections, or parasitic infestations that disrupt the functioning of the digestive system. Therefore, research on the morphology of Blastocystis hominis is necessary to aid in the diagnosis of diarrhea. This study is an experimental investigation conducted on Jones culture medium that has been altered with fetal bovine serum. The study consists of five trial groups with different volume: P1 (0.1 mL), P2 (0.5 mL), P3 (1.0 mL), P4 (1.5 mL), and P5 (2.0 mL). The morphological findings of Blastocystis hominis in each trial group, with pH averages P1 (7.29), P2 (7.27), P3 (7.30), dan P4 (7.31), were examined microscopically. The results were found to be optimal, with a statistical value of $P > 0.05$ in the independent t-test. The P5 test group (6.15) differed significantly from the gold standard at $P < 0.001$. The fetal bovine serum can be utilized for clinical reasons at a volume of 0.1 mL and a pH of 7.29, as it is already capable of displaying morphological results.

1. INTRODUCTION

Diarrhea is the third leading cause of mortality among children under the age of 5 globally, resulting in the demise of around 443,832 children annually. The source cited is the World Health Organization (WHO) in the year 2024. According to the Indonesian Ministry of Health (Almasi et al., 2022; Permenkes, 2020), it is also established that diarrhea is responsible for 7% of newborn mortality in Indonesia. Diarrhea is the result of infections caused by bacteria, viruses, and parasites. Blastocystis hominis is one of the parasites most frequently responsible for diarrhea (Deng et al., 2019; Hublin et al., 2021). Improper treatment of diarrhea can result in complications since the underlying pathogen responsible for the condition is not effectively addressed, allowing it to persist and progress. Microscopic, culture, and molecular studies are employed to validate the diagnosis of Blastocystis hominis infection (Aldahasi et al., 2020; Padukone et al., 2018). The microscopic examination allows for the identification of the main physical characteristics and reproductive processes of Blastocystis hominis (Ahmed & Karanis, 2019; Elsayad, Mona et al., 2019). The transient transformation of the vacuolar structure into an ameboid form in Blastocystis hominis results in the progression from asymptomatic to symptomatic due to pathological growth. Demonstrated that the pH level has a significant impact on the survival and physical characteristics of

*Corresponding author.

E-mail addresses: bayu.permasutha@undiksha.ac.id (Made Bayu Permasutha)

Blastocystis hominis. Specifically, *Blastocystis hominis* requires a pH that is neither acidic nor basic in order to grow properly (Mahmoud et al., 2023; ZAKI et al., 2024).

Blastocystis hominis is found globally, with a prevalence ranging from 1% to 30%. Developing countries and locations with poor sanitation have a higher prevalence compared to developed regions with acceptable sanitary practices. Nevertheless, the precise mechanism by which this protozoan causes disease is still a subject of debate, despite professionals successfully diagnosing and treating infected people. The prevalence of *Blastocystis hominis* is estimated to occur in 58% of the Indonesian population during one episode of infection. *Blastocystis* isolates from humans and non-human animals share morphological similarities and can be vacuolar, granular, cystic, or amoeboid. The encystation stage refers to the transformation of the amoeboid and multivacuolar forms into the infectious form, known as a cyst (Abdullah & Dyary, 2023; Rozi, 2019). A positive diagnosis of *B. hominis* infection in a clinical environment is contingent upon the presence of the cystic stage or the confirmation of vacuolar, granular, or amoebic forms in diarrhea samples. The vacuolar morphology of *Blastocystis hominis* exhibits a unique central body, resulting in a remarkably low diagnostic accuracy. On the other hand, vacuolar forms and others can easily be confused with other intestinal protozoa (Hegazy et al., 2021; Science, 2023). According to multiple studies, individuals who do not show symptoms of a disease often test positive for the vacuolar phase. The granular form (3-80 µm) is characterized by the presence of several granules inside the cytoplasm, together with two nuclei. This form closely resembles the vacuolar type. Moreover, the presence of the granular phase is indicative of cellular demise, and it is frequently found in mature cultures or in the culture medium supplemented with antibiotics. The amoeboid form, measuring 2.6-7.8 µm, exhibits a distinct resemblance to macrophages and neutrophils. It is equipped with two pseudopodia and a sizable vacuole within the cytoplasm (Goleń et al., 2020; Mylvaganam et al., 2021). Pseudopodia is crucial for adhering to the mucous membrane of the gut. The pathogenic subtype of *Blastocystis hominis* cultures contain an amoeboid form, which leads to various gastrointestinal issues in patients. The cystic form, measuring 3-6 µm, has 1-4 nuclei and possesses a multilayered wall that enables it to remain viable for up to a month in the external environment. Consequently, it has the potential to trigger epidemics among the susceptible demographic, particularly children (Davies et al., 2020; Gaythorpe et al., 2021).

The detection and identification of *Blastocystis hominis* is still challenging due to its morphological alterations, which greatly complicate the diagnosis of this infection. The culture approach combined with immunoserological testing demonstrates the highest sensitivity for detecting *Blastocystis hominis*. Previous research have demonstrated that the usage of Jones media exhibited greater cultural sensitivity in comparison to polymerase chain reaction (PCR) (Lawrence Panchali et al., 2022; Schoonbroodt et al., 2022). Prior research included three serum modifications: horse serum, human serum, and donkey serum, with horse serum being the major serum used. Previous research conducted using horse serum in an in vitro method found that between pH 7.0 and 7.5, vacuolar, granular, amoeboid, and cyst morphologies were seen. However, pH 8.0, certain parasites exhibited irregularities and were difficult to distinguish. Horse serums are costly, inaccessible, and have a propensity to harm cells, rendering them useless for promoting cell proliferation. Highly sensitive serums, such as fetal bovine serums, which are more effective than horse serum, can be readily found at a reasonable cost without causing harm to cells. Fetal bovine serum is commonly used in cell cultures, including cancer cell culture SKBR3, follicle culture, and goat PE oocyte quality on TCM culture medium 199, as well as in improving the post-vitro maturation rate of cow oocytes. This is due to its effective growth factors (Ahn et al., 2020; Suren et al., 2020).

Extensive study has demonstrated the efficacy of fetal bovine serum. However, a suitable pH for the utilization of Jones culture medium has not yet been identified. Imbalanced pH levels can lead to the formation of wrinkles, making it difficult to detect *Blastocystis hominis*. Extensive study has demonstrated the efficacy of fetal bovine serum. However, a suitable pH for the utilization of Jones culture medium has not yet been identified. Inappropriate pH will induce wrinkles, preventing *Blastocystis hominis* from being detected, complicating research. Therefore, more research is needed on pH changes in the use of fetal bovine serum in modified Jones culture medium to determine the morphological picture of *Blastocystis hominis*.

2. METHOD

Study Population

A cross-sectional study conducted in RSUD Buleleng and Puskesmas Buleleng polyclinics between May and November 2021 collected 35 samples of parasite diarrhea that tested positive. As a means of engagement, we are instructed to endorse a letter. After the patient has completed defecation, the stool sample is collected in a sterile container and stored in an ice box. The samples underwent examination at the Medical Faculty Laboratory and the Faculty of Mathematics and Natural Sciences at Ganesha University of Education. The specimens were categorized into two methods for investigation: direct microscope

examination and culture. The study has received approval from the Ethics Committee of Ganesha University of Education.

Microscopic and Culture

The Jones culture medium was modified by including fetal bovine serum. The volumes used for each treatment are as follows: P1 (0.1 mL), P2 (0.5 mL), P3 (1.0 mL), and P5 (2.0 mL). The specimens were acquired by collecting fecal samples from patients suffering from diarrhea, utilizing containers specifically designed for collecting stool. Cultivation was initiated by introducing 50 mg of feces into the prepared culture medium and incubating it at a temperature of 37°C. pH measurements will be taken for every treatment at 24, 48, and 72 hours. At the same time, microscopic inspection was used to describe main and reproductive morphological features of *Blastocystis hominis*.

Statistical Analysis

Morphological analysis is performed using the independent t-test to see the significance of the average of pH at P1, P2, P3, P4, and P5 against positive controls as gold standard. The variable is considered statistically significant when $P < 0.05$, indicating a meaning that is significantly different from the control variable. If $P > 0.05$, it indicates that the variable is not statistically significant, meaning that it is not significantly different from the control variable.

3. RESULT AND DISCUSSION

Result

The morphological findings of the test groups P1, P2, P3, P4, and P5 were tested at 24, 48 and 72 hours and the pH ratio as follows.

Table 1. Morphological Findings of *Blastocystis Hominis* In Microscopic

| Variable | Time | Main Morphology Findings | Reproductive Morphology Findings |
|-------------------------|---------|------------------------------------|-------------------------------------|
| Positive Control | - | Vacuolar, granular, amoeboid, cyst | Budding, binary fission, plasmotomy |
| Negative Control | - | No visible parasite is present | No visible parasite is present |
| P1 (0.1 mL) | 24 hour | Vacuolar, granular | Budding, binary fission |
| | 48 hour | Vacuolar, granular | Budding, binary fission |
| | 72 hour | Vacuolar, granular, cyst | Budding, binary fission |
| P2 (0.5 mL) | 24 hour | Vacuolar, granular | Budding, binary fission |
| | 48 hour | Vacuolar, granular | Budding, binary fission |
| | 72 hour | Vacuolar, granular, cyst | Budding, binary fission |
| P3 (1.0 mL) | 24 hour | Vacuolar, granular, amoeboid | Budding, binary fission, plasmotomy |
| | 48 hour | Vacuolar, granular, amoeboid | Budding, binary fission, plasmotomy |
| | 72 hour | Vacuolar, granular, amoeboid, cyst | Budding, binary fission, plasmotomy |
| P4 (1.5 mL) | 24 hour | Vacuolar, granular, amoeboid | Budding, binary fission, plasmotomy |
| | 48 hour | Vacuolar, granular, amoeboid | Budding, binary fission, plasmotomy |
| | 72 hour | Vacuolar, granular, amoeboid, cyst | Budding, binary fission, plasmotomy |
| P (2.0 mL) | 24 hour | Wrinkle formation vacuolar | Budding, binary fission |
| | 48 hour | Wrinkle formation vacuolar | Budding, binary fission |
| | 72 hour | Wrinkle formation vacuolar | Budding, binary fission |

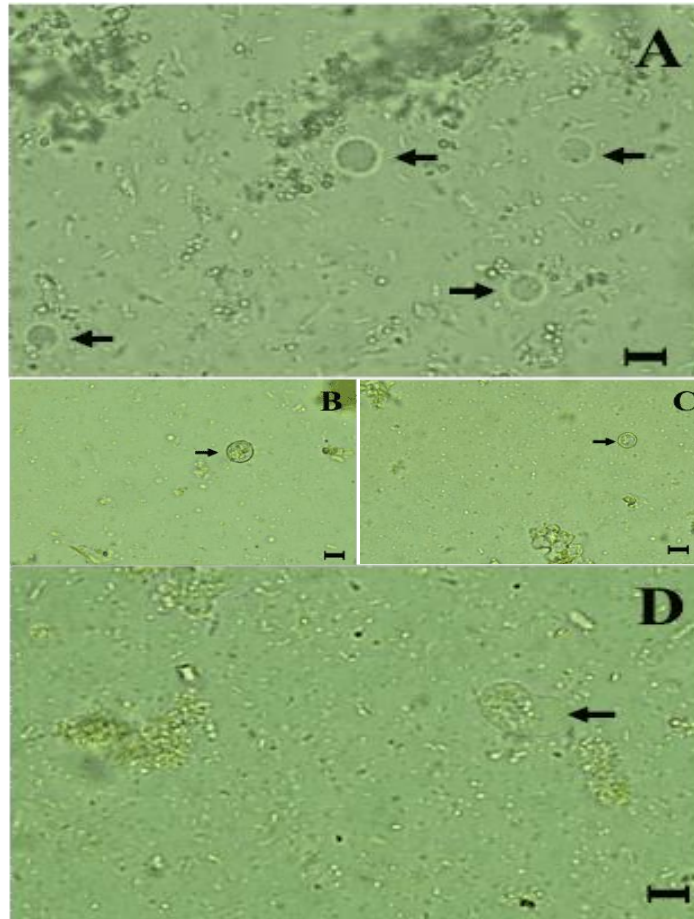


Figure 1. Main Morphological Test Results of *Blastocystis Hominis* Culture at Strong Magnification (indicated by Arrow Mark) at 24, 48, and 72 Hours. (a) The Vacuolar form; (b) the Granular; (c) the; (d) the Amoeboid form (Pseudopodia are Indicated by Arrows). Scale bar: 10 μ m

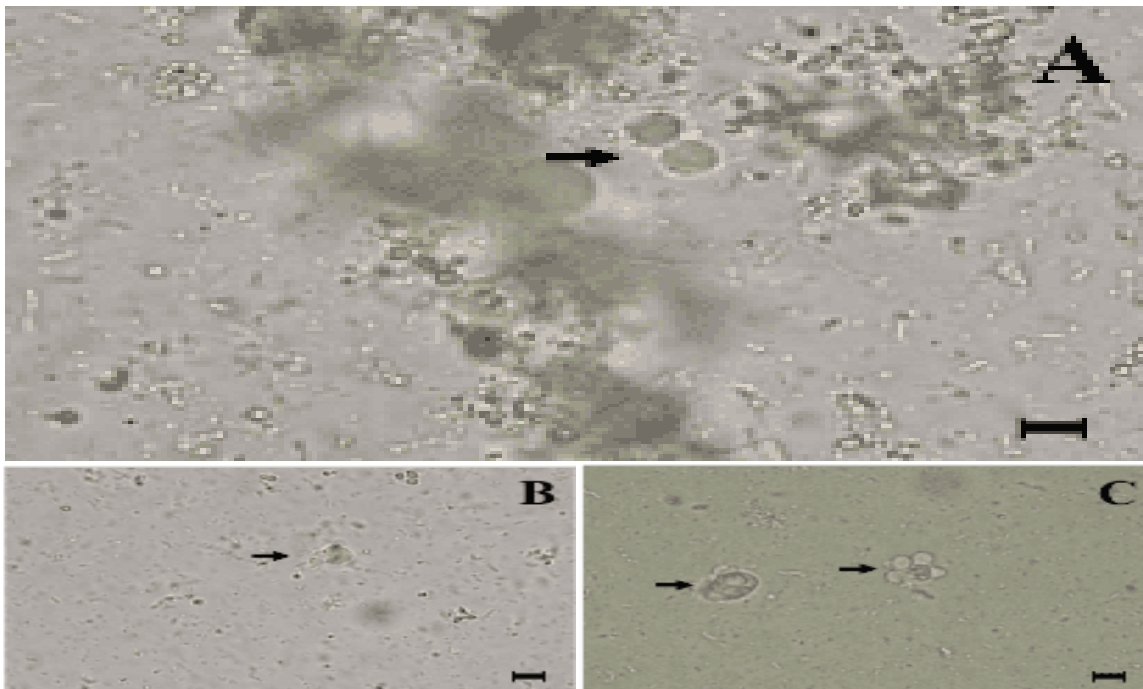


Figure 2. Reproductive Morphology test Results of *Blastocystis Hominis* culture at Strong Magnification (indicated by Arrows) at 24, 48, and 72 Hours. (a) Binary Splitting Shape; (b) Plasmotomy form; (c) Budding. Scale bar: 10 μ m

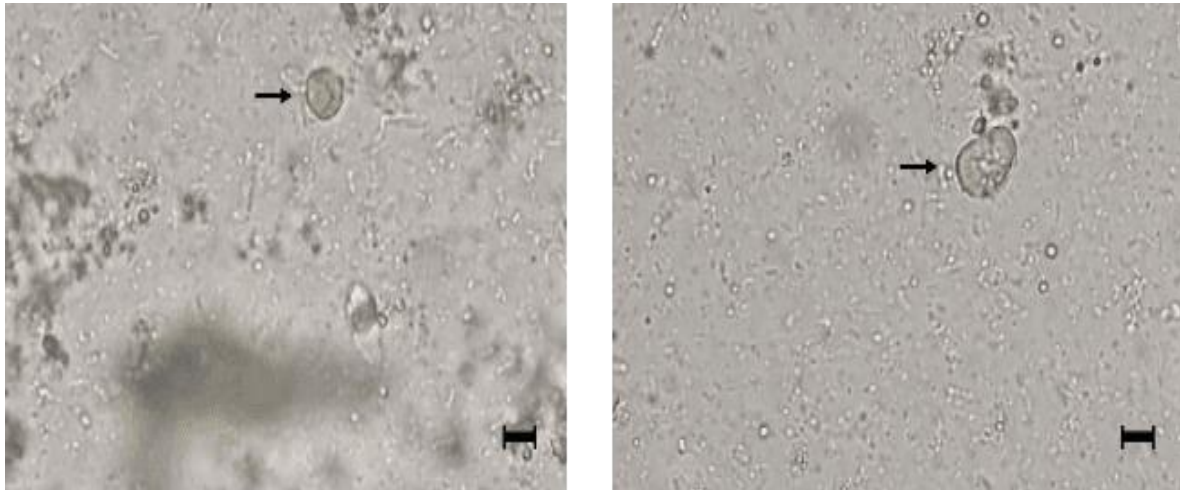


Figure 3. *Blastocystis Hominis* Morphology Test Results in P5 test Group (Indicated by Arrows). See a Picture of the Curved Vacuolar Morphology as well as an Image of a Perfectly Irregular cyst. Scale bar: 10 μ m

On the modified culture medium Jones obtained a picture of his main form and reproductive at 24, 48, and 72 hours. In groups P1 and P2 only vacuolar, granular, and cyst forms appear in the main morphology. Reproductive morphologies in this group show budding and binary fission. Groups P3 and P4 show the whole main forms, vacuolar, granular, ameboid, and cysts. Furthermore, there are also reproductive morfologies such as binary fission, plasmotomy, and budding. The test group P5 shows the main morphological picture of wrinkle vacuolar forms and irregular cyst walls.

Table 2. Table of Independent T-test Results

| No. | Positive Control* | P1 (0.1 mL) | P2 (0.5 mL) | P3 (1 mL) | P4 (1.5 mL) | P5 (2.0 mL) |
|---------------------------------|-----------------------------------|-----------------------------------|-----------------------------------|-----------------------------------|-----------------------------------|-----------------------------------|
| 1. | 7.29 | 7.29 | 7.26 | 7.30 | 7.31 | 6.15 |
| 2. | 7.30 | 7.30 | 7.28 | 7.27 | 7.28 | 6.18 |
| 3. | 7.26 | 7.28 | 7.27 | 7.30 | 7.34 | 6.13 |
| 4. | 7.28 | 7.28 | 7.25 | 7.32 | 7.32 | 6.14 |
| 5. | 7.30 | 7.30 | 7.29 | 7.31 | 7.30 | 6.15 |
| Mean \pm SD | 7.28 \pm 0.01 | 7.29 \pm 0.01 | 7.27 \pm 0.01 | 7.30 \pm 0.01 | 7.31 \pm 0.02 | 6.15 \pm 0.01 |
| Data normality | 0.314 | 0.119 | 0.967 | 0.453 | 1.000 | 0.453 |
| P value** | | 0.659 | 0.159 | 0.248 | 0.091 | <0.001 |

*This inspection serves as the gold standard.

**The significance of the difference in average pH can be determined using the independent t-test.

According to the provided table, there is no statistically significant difference in the average pH test results among the P1, P2, P3, and P4 test groups compared to the gold standard ($P > 0.05$). The P5 test group exhibited statistically significant differences ($P < 0.001$). The morphological results of the P1, P2, P3, and P4 that there was no difference of the positive control group. Significant differences were observed only in the P5 group when compared to the positive controls.

Discussion

Diarrhea was the second leading cause of post-pneumonia fatalities in the post-neonatal period (29 days - 11 months), increasing 14% from 2020 and accounting for 9.8% of all deaths. Furthermore, diarrhea is the leading cause of death in the group of young children (12 - 5 months), accounting for 10.3% of deaths, an increase of 4.55% from 2020 (Kemenkes, 2021b). According to the Indonesian Nutrition Status Survey 2021, the occurrence of diarrhoea is 9.8% (Kemenkes, 2021a). Based on the national data, it is evident that despite a drop in the number of cases, diarrhoea continues to be the leading cause of suffering and mortality among other diseases (Hasan et al., 2021; Kemenkes, 2020; Ugboko et al., 2020).

Diarrhea is a consequence of illnesses caused by bacteria, viruses, and parasites (Almasi et al., 2022; Hublin et al., 2021; Mahmood et al., 2021; Saha et al., 2022). Parasite infestation is a significant global health issue, affecting around 3.5 billion individuals worldwide. Parasite infections result in 450 million cases of illness and 200,000 deaths per year. Protozoa infections, including *Blastocystis hominis*, are one of the causes of diarrhea associated with these infections (Deng et al., 2019; Tegen et al., 2020). The prevailing parasite is currently detected in human fecal samples, exhibiting a greater occurrence in underdeveloped nations (50-60%) compared to wealthy nations (about 10% or less). *Blastocystis hominis* is a highly polymorphic parasite that exhibits several kinds of morphology, such as vacuolar, non-vacuolar, granular, amoeboid, and cyst forms. It can be transmitted through the fecal-oral route, particularly under unsanitary environments. *Blastocystis hominis* is one of the parasites most frequently responsible for diarrhea (Fahim et al., 2021; Rossi et al., 2024). The prevalence of *Blastocystis* infection is higher than that of other intestinal parasites, such as *Giardia*, *Entamoeba*, or *Cryptosporidium*. The majority of *Blastocystis* isolates detected in fecal samples exist in either cyst or vacuolar forms (Candela et al., 2021; Tapia-Veloz et al., 2023). The amoeboid type is infrequently observed, however it is mostly linked to symptoms. Thus, it is likely that the amoeboid forms of *Blastocystis* are pathogenic. On the other hand, gastrointestinal or dermatological symptoms such as diarrhea, bloating, nausea, vomiting, urticaria, or, less frequently, severe itching or urticaria, as well as iron deficiency anemia, were also found to be exclusively caused by *Blastocystis hominis* (Matovelle et al., 2022; Rudzińska & Sikorska, 2023).

The diagnosis of *Blastocystis hominis* infection can be confirmed using microscopic, culture, and molecular test (Aldahasi et al., 2020; Mahmoud et al., 2023). The microscopic examination allows for the observation of the main physical characteristics and reproductive processes of *Blastocystis hominis* (Ahmed & Karanis, 2019; Mahmoud et al., 2023). The transient transformation of the vacuolar structure into an amoeboid form in *Blastocystis hominis* results in the progression from asymptomatic to symptomatic due to pathological growth. *Blastocystis* isolates from humans and non-human animals share morphological similarities and can be vacuolar, granular, cystic, or amoeboid. The encystation stage refers to the transformation of the amoeboid and multivacuolar forms into the infectious form, known as a cyst (Badparva & Kheirandish, 2020; Rozi, 2019). A positive diagnosis of *B. hominis* infection in a clinical environment is contingent upon the presence of the cystic stage or the confirmation of vacuolar, granular, or amoebic forms in diarrhea samples. The vacuolar morphology of *Blastocystis hominis* exhibits a unique central body, resulting in a remarkably low diagnostic accuracy. On the other hand, vacuolar forms and others can easily be confused with other intestinal protozoa (Guilavogui et al., 2022; Markell & Udkow, 2023).

Identification of *Blastocystis hominis* infection can be challenging due to the presence of other dangerous parasites that exhibit comparable circumstances, such as *Giardia lamblia*, *Entamoeba histolytica*, and *Trichomonas vaginalis* (Barrow et al., 2020; Sood, 2022). Other than, The detection and identification of *Blastocystis hominis* is still challenging due to its morphological alterations, which greatly complicate the diagnosis of this infection. The culture approach combined with immunoserological testing demonstrates the highest sensitivity for detecting *Blastocystis hominis*. Previous studies have demonstrated that the use of Jones medium resulted in greater culture sensitivity when compared to polymerase chain reaction (PCR). Fetal bovine serum is commonly used in cell cultures, including cancer cell culture SKBR3, follicle culture, and goat PE oocyte quality on TCM culture medium 199, as well as in improving the post-vitro maturation rate of cow oocytes. This is due to its effective growth factors (Reyes-López et al., 2022; Sood, 2022).

Jones culture medium was modified by adding fetal bovine serum in the following volumes: P1 (0.1 mL), P2 (0.5 mL), P3 (1.0 mL), P4 (1.5 mL), and P5 (2.0 mL). Microscopic investigation revealed the main morphological and reproductive characteristics of *Blastocystis hominis* at 24, 48, and 72 hours. The main morphological types identified in groups P1 and P2 were vacuolar, granular, and cyst. This group's reproductive morphology is determined by binary fission and budding. Groups P3 and P4 exhibited all of the major morphologies, including vacuolar, granular, amoeboid, and cyst. The reproductive morphology includes three processes: binary fission, plasmotomy, and budding. The main morphological features in the P5 test group were a vacuolar shape with wrinkled walls and an irregular-walled cyst. There was no reproductive morphology in this group.

The best morphological findings in the microscopic examination were seen in test groups P3 and P4, with average pH values of 7.30 and 7.31. Groups P1 and P2 which had average pH values of 7.29 and 7.27, they are unable to demonstrate amoeboid and plasmotomy characteristics. Meanwhile, in group P5 with a pH of 6.15, the worst morphological appearance is observed, characterized by vacuolar wall morphology and wrinkled cysts. Indicates that the pH level affects the viability and morphology of *Blastocystis hominis*, wherein the organism requires a neutral pH to grow (Ismail et al., 2022; Sharpe, 2022). Utilized six media, specifically Jones medium mixed with 10% horse serum. These media were generated with decreasing pH values of 6, 5, 4, 3, 2, and 1, and the pH was altered by adding 0.1M HCl. Additionally, a control medium with a pH of 7 was also created. Previous research conducted using horse serum in an

in vitro method found that between pH 7.0 and 7.5, vacuolar, granular, ameboid, and cyst morphologies were seen. However, pH 8.0, certain parasites exhibited irregularities and were difficult to distinguish. This supporting the study by using a modified Jones culture medium, which results in ideal morphology for *Blastocystis hominis* at neutral pH and wrinkle morphology findings at acidic pH, or 6.15 at P5 group (Guilavogui et al., 2022; Markell & Udkow, 2023).

The average pH test results in this study were analyzed using an independent t-test to determine the significance of each test group compared to the positive control group as the gold standard. P1 (7.29), P2 (7.27), P3 (7.30), and P4 (7.31) have a $P > 0.05$. There are no significant differences between the group in question and the standard gold. Furthermore, P5 (6.15) have a $P < 0.001$. There are significant differences in this group compared to gold standards (Ahmed & Karanis, 2019; Tegen et al., 2020). Therefore, this study's findings indicate that the morphology of *Blastocystis hominis* is significantly impacted by pH differences. The utilization of fetal bovine serum at a volume of 0.1 mL with a pH of 7.29 in Jones culture medium is sufficient to demonstrate the morphological characteristics of *Blastocystis hominis* for diagnostic purposes. However, a volume of 1.0 mL with a pH of 7.30 can be used to provide a complete morphological picture (Almasi et al., 2022; Deng et al., 2019).

The future benefit of this research is that it can serve as a reference for the use of fetal bovine serum in healthcare services, as it can be utilized in many cultures. Fetal bovine serum is affordable, readily available, and possesses excellent growth factors that do not harm cells and promote optimal cell growth. A comprehensive clinical practice guide for the diagnostic testing of *Blastocystis hominis* infection in a hospital setting. This is done to streamline the identification of diarrhea caused by the parasite *Blastocystis hominis* in order to ensure appropriate treatment for the patient. Gathered precise epidemiology data. This was undertaken in an effort to streamline the gathering of epidemiological study data on instances of diarrhea caused by the parasite *Blastocystis hominis* in a specific area.

4. CONCLUSION

The main morphological and reproductive observations of *Blastocystis hominis* were identified in P1, P2, P3, and P4. From a clinical perspective, the unintentional use of fetal bovine serum in modified Jones culture medium. The main morphological types identified in groups P1 and P2 were vacuolar, granular, and cyst. This group's reproductive morphology is determined by binary fission and budding. Groups P3 and P4 exhibited all of the major morphologies, including vacuolar, granular, ameboid, and cyst. The reproductive morphology includes three processes: binary fission, plasmotomy, and budding.

5. REFERENCES

- Abdullah, S. H., & Dyary, H. O. (2023). Epizootiology of *Blastocystis* spp.: A Parasite with Zoonotic Concern. *International Journal of Agriculture and Biosciences, Zoonosis Volume 2*, 261–274. <https://doi.org/10.47278/book.zoon/2023.69>.
- Ahmed, S. A., & Karanis, P. (2019). *Blastocystis* spp., ubiquitous parasite of human, animals and environment. In *Encyclopedia of Environmental Health* (pp. 429–435). Elsevier. <https://doi.org/10.1016/B978-0-12-409548-9.10947-9>.
- Ahn, Y., Gibson, B., Williams, A., Alusta, P., Buzatu, D. A., Lee, Y. J., LiPuma, J. J., Hussong, D., Marasa, B., & Cerniglia, C. E. (2020). A comparison of culture-based, real-time PCR, droplet digital PCR and flow cytometric methods for the detection of *Burkholderia cepacia* complex in nuclease-free water and antiseptics. *Journal of Industrial Microbiology and Biotechnology*, 47(6–7), 475–484. <https://doi.org/10.1007/s10295-020-02287-3>.
- Aldahasi, W., TOULAH, F., & WAKID, M. (2020). Evaluation of Common Microscopic Techniques for Detection of *Blastocystis Hominis*. *Journal of the Egyptian Society of Parasitology*, 50(1), 33–40. <https://doi.org/10.21608/jesp.2020.88748>.
- Almasi, A., Zangeneh, A., Ziapour, A., Saeidi, S., Teimouri, R., Ahmadi, T., Khezeli, M., Moradi, G., Soofi, M., Salimi, Y., Rajabi-Gilan, N., Ramin Ghasemi, S., Heydarpour, F., Moghadam, S., & Yigitcanlar, T. (2022). Investigating Global Spatial Patterns of Diarrhea-Related Mortality in Children Under Five. *Frontiers in Public Health*, 10(July), 1–9. <https://doi.org/10.3389/fpubh.2022.861629>.
- Badparva, E., & Kheirandish, F. (2020). *Blastocystis hominis*: A pathogenic parasite. *Archives of Clinical Infectious Diseases*, 15(4), 1–6. <https://doi.org/10.5812/archcid.97388>.
- Barrow, P., Dujardin, J. C., Fasel, N., Greenwood, A. D., Osterrieder, K., Lomonosoff, G., Fiori, P. L., Atterbury, R., Rossi, M., & Lalle, M. (2020). Viruses of protozoan parasites and viral therapy: Is the time now right? *Virology Journal*, 17(1), 1–14. <https://doi.org/10.1186/s12985-020-01410-1>.
- Candela, E., Goizueta, C., Periago, M. V., & Muñoz-Antoli, C. (2021). Prevalence of intestinal parasites and

- molecular characterization of *Giardia intestinalis*, *Blastocystis* spp. and *Entamoeba histolytica* in the village of Fortín Mbororé (Puerto Iguazú, Misiones, Argentina). *Parasites and Vectors*, 14(1), 1–15. <https://doi.org/10.1186/s13071-021-04968-z>.
- Davies, N. G., Klepac, P., Liu, Y., Prem, K., Jit, M., Pearson, C. A. B., Quilty, B. J., Kucharski, A. J., Gibbs, H., Clifford, S., Gimma, A., van Zandvoort, K., Munday, J. D., Diamond, C., Edmunds, W. J., Houben, R. M. G. J., Hellewell, J., Russell, T. W., Abbott, S., ... Eggo, R. M. (2020). Age-dependent effects in the transmission and control of COVID-19 epidemics. *Nature Medicine*, 26(8), 1205–1211. <https://doi.org/10.1038/s41591-020-0962-9>.
- Deng, L., Chai, Y., Zhou, Z., Liu, H., Zhong, Z., Hu, Y., Fu, H., Yue, C., & Peng, G. (2019). Epidemiology of *Blastocystis* sp. infection in China: A systematic review. *Parasite*, 26. <https://doi.org/10.1051/parasite/2019042>.
- Elsayad, Mona, E., TOLBA, M., ARGIAH, H., GABALLAH, A., OSMAN, M., & MIKHAEL, I. (2019). Electron Microscopy of *Blastocystis Hominis* and Other Diagnostic Approaches. *Journal of the Egyptian Society of Parasitology*, 49(2), 373–380. <https://doi.org/10.21608/jesp.2019.68145>.
- Fahim, S. M., Gazi, M. A., Hasan, M. M., Alam, M. A., Das, S., Mahfuz, M., Rahman, M. M., Haque, R., Sarker, S. A., & Ahmed, T. (2021). Infection with *blastocystis* spp. And its association with enteric infections and environmental enteric dysfunction among slum-dwelling malnourished adults in Bangladesh. *PLoS Neglected Tropical Diseases*, 15(8), 1–15. <https://doi.org/10.1371/journal.pntd.0009684>.
- Gaythorpe, K. A. M., Bhatia, S., Mangal, T., Unwin, H. J. T., Imai, N., Cuomo-Dannenburg, G., Walters, C. E., Jauneikaite, E., Bayley, H., Kont, M. D., Mousa, A., Whittles, L. K., Riley, S., & Ferguson, N. M. (2021). Children's role in the COVID-19 pandemic: a systematic review of early surveillance data on susceptibility, severity, and transmissibility. *Scientific Reports*, 11(1), 1–14. <https://doi.org/10.1038/s41598-021-92500-9>.
- Goleń, J., Tyszk, J., Bickmeyer, U., & Bijma, J. (2020). SiR-actin-labelled granules in foraminifera: patterns, dynamics, and hypotheses. *Biogeosciences*, 17(4), 995–1011. <https://doi.org/10.5194/bg-17-995-2020>.
- Guilavogui, T., Gantois, N., Even, G., Desramaut, J., Dautel, E., Denoyelle, C., Cissé, F. I., Touré, S. C., Kourouma, B. L., Sawant, M., Chabé, M., Certad, G., & Viscogliosi, E. (2022). Detection, Molecular Identification and Transmission of the Intestinal Protozoa *Blastocystis* sp. in Guinea from a Large-Scale Epidemiological Study Conducted in the Conakry Area. *Microorganisms*, 10(2). <https://doi.org/10.3390/microorganisms10020446>.
- Hasan, S. M. T., Das, S., Faruque, A. S. G., Khan, A. I., Clemens, J. D., & Ahmed, T. (2021). Taking care of a diarrhea epidemic in an urban hospital in bangladesh: Appraisal of putative causes, presentation, management, and deaths averted. *PLoS Neglected Tropical Diseases*, 15(11), 1–23. <https://doi.org/10.1371/journal.pntd.0009953>.
- Hegazy, L. A., Salama, M. A., Fawzy, E. M., Saleh, A. A., & Maghawry, A. A. (2021). Evaluation of Jones' Medium Culture versus Locke Egg Medium in Diagnosis of *Blastocystis Hominis*. *Annals of R.S.C.B.*, 25(5), 987–1001. <http://annalsofrscb.rohttp://annalsofrscb.ro>.
- Hublin, J. S. Y., Maloney, J. G., & Santin, M. (2021). *Blastocystis* in domesticated and wild mammals and birds. In *Research in Veterinary Science* (Vol. 135, pp. 260–282). Elsevier B.V. <https://doi.org/10.1016/j.rvsc.2020.09.031>.
- Ismail, R. M., Saleh, A. H., & Ibrahim, H. J. (2022). Study the Life Cycle and Some Other Characterized of *Blastocystis Hominis*:(Subject Review). *World Bulletin of Public Health*, 15(October), 148–155.
- Kemenkes, R. I. (2020). *Rencana Aksi Nasional Penanggulangan Pneumonia dan Diare 2023-2030*.
- Kemenkes, R. I. (2021a). *Hasil Studi Status Gizi Indonesia (SSGI) Tingkat Nasional, Provinsi, dan Kabupaten/Kota Tahun 2021*.
- Kemenkes, R. I. (2021b). *Profil Kesehatan Indonesia*.
- Lawrence Panchali, M. J., Oh, H. J., Lee, Y. M., Kim, C.-M., Tariq, M., Seo, J.-W., Kim, D. Y., Yun, N. R., & Kim, D.-M. (2022). Accuracy of Real-Time Polymerase Chain Reaction in COVID-19 Patients. *Microbiology Spectrum*, 10(1). <https://doi.org/10.1128/spectrum.00591-21>.
- Mahmood, R. M. U., Alfatlawi, I. O., & Jawd, D. S. M. (2021). Review on Causes of Diarrhea (Bacterial, Parasitic, Viral) in Children. *Journal of Clinical Trials and Regulations*, 3(1), 14–20.
- Mahmoud, A. M., Ismail, K. A., Khalifa, O. M., Abdel-wahab, M. M., Hagag, H. M., & Mahmoud, M. K. (2023). Molecular Identification of *Blastocystis hominis* Isolates in Patients with Autoimmune Diseases. *Applied Microbiology*, 3(2), 417–428. <https://doi.org/10.3390/applmicrobiol3020029>.
- Markell, E. K., & Udkow, M. P. (2023). *Blastocystis hominis*. *Western Journal of Medicine*, 152(6), 721. <https://doi.org/10.1097/00006454-198908000-00036>.
- Matovelle, C., Tejedor, M. T., Monteagudo, L. V., Beltrán, A., & Quílez, J. (2022). Prevalence and Associated Factors of *Blastocystis* sp. Infection in Patients with Gastrointestinal Symptoms in Spain: A Case-

- Control Study. *Tropical Medicine and Infectious Disease*, 7(9). <https://doi.org/10.3390/tropicalmed7090226>.
- Mylvaganam, S., Freeman, S. A., & Grinstein, S. (2021). The cytoskeleton in phagocytosis and macropinocytosis. *Current Biology*, 31(10), R619–R632. <https://doi.org/10.1016/j.cub.2021.01.036>.
- Padukone, S., Mandal, J., Rajkumari, N., Bhat, B., Swaminathan, R., & Parija, S. (2018). Detection of Blastocystis in clinical stool specimens using three different methods and morphological examination in Jones' medium. *Tropical Parasitology*, 8(1), 33–40. https://doi.org/10.4103/tp.TP_4_18.
- Permenkes, R. I. (2020). *Peraturan Menteri Kesehatan Republik Indonesia*.
- Reyes-López, M., Ramírez-Rico, G., Serrano-Luna, J., & de la Garza, M. (2022). Activity of Apo-Lactoferrin on Pathogenic Protozoa. *Pharmaceutics*, 14(8). <https://doi.org/10.3390/pharmaceutics14081702>.
- Rossi, F., Amadoro, C., Santonicola, S., Marino, L., & ... (2024). *Protozoan Infections Acquired from Food or Drinking Water: An Update*. <https://doi.org/10.20944/preprints202403.1207.v1>.
- Rozi, M. (2019). Blastocytosis hominis: Unboxing Its Clinical Significance. *Sumatera Medical Journal*.
- Rudzińska, M., & Sikorska, K. (2023). Epidemiology of Blastocystis Infection: A Review of Data from Poland in Relation to Other Reports. *Pathogens*, 12(8). <https://doi.org/10.3390/pathogens12081050>.
- Saha, J., Mondal, S., Chouhan, P., Hussain, M., Yang, J., & Bibi, A. (2022). Occurrence of Diarrheal Disease among Under-Five Children and Associated Sociodemographic and Household Environmental Factors: An Investigation Based on National Family Health Survey-4 in Rural India. *Children*, 9(5). <https://doi.org/10.3390/children9050658>.
- Schoonbroodt, S., Ichanté, J. L., Boffé, S., Devos, N., Devaster, J. M., Taddei, L., Rondini, S., Arora, A. K., Pascal, T., & Malvaux, L. (2022). Real-time PCR has advantages over culture-based methods in identifying three major airway bacterial pathogens in chronic obstructive pulmonary disease: Results from three clinical studies in Europe and North America. *Frontiers in Microbiology*, 13(February), 1–13. <https://doi.org/10.3389/fmicb.2022.1098133>.
- Science, F. O. F. (2023). *MASTER ' S THESIS*. October, 1–90.
- Sharpe, D. M. R. (2022). *Hiv-1127-2022(586-592)*.
- Sood, R. (2022). Medical Parasitology. *Concise Book of Medical Laboratory Technology: Methods and Interpretations*, 142–142. https://doi.org/10.5005/jp/books/10169_8.
- Suren, C., Feihl, S., Cabric, S., Banke, I. J., Haller, B., Trampuz, A., von Eisenhart-Rothe, R., & Prodinger, P. M. (2020). Improved pre-operative diagnostic accuracy for low-grade prosthetic joint infections using second-generation multiplex Polymerase chain reaction on joint fluid aspirate. *International Orthopaedics*, 44(9), 1629–1637. <https://doi.org/10.1007/s00264-020-04552-7>.
- Tapia-Veloz, E., Gozalbo, M., Guillén, M., Dashti, A., Bailo, B., Köster, P. C., Santín, M., Carmena, D., & Trelis, M. (2023). Prevalence and associated risk factors of intestinal parasites among schoolchildren in Ecuador, with emphasis on the molecular diversity of *Giardia duodenalis*, *Blastocystis* sp. and *Enterocytozoon bieneusi*. *PLoS Neglected Tropical Diseases*, 17(5), 1–21. <https://doi.org/10.1371/journal.pntd.0011339>.
- Tegen, D., Damtie, D., & Hailegebriel, T. (2020). Prevalence and Associated Risk Factors of Human Intestinal Protozoan Parasitic Infections in Ethiopia: A Systematic Review and Meta-Analysis. *Journal of Parasitology Research*, 2020. <https://doi.org/10.1155/2020/8884064>.
- Ugboko, H. U., Nwinyi, O. C., Oranusi, S. U., & Oyewale, J. O. (2020). Childhood diarrhoeal diseases in developing countries. *Heliyon*, 6(4), e03690. <https://doi.org/10.1016/j.heliyon.2020.e03690>.
- ZAKI, W., RAGEH, M., & ELMOAMALY, A. (2024). Assessment of Microscopic Examination and in-Vitro Culture Compared To Pcr for Diagnosing Blastocystosis. *Journal of the Egyptian Society of Parasitology*, 54(1), 87–94. <https://doi.org/10.21608/jesp.2024.351359>.